



## Right parietal contributions to verbal working memory: Spatial or executive?

Susan M. Ravizza<sup>b,d,\*</sup>, Marlene Behrmann<sup>c,d</sup>, Julie A. Fiez<sup>a,b,d</sup>

<sup>a</sup> Department of Neuroscience, University of Pittsburgh, USA

<sup>b</sup> Department of Psychology, University of Pittsburgh, USA

<sup>c</sup> Department of Psychology, Carnegie Mellon University, USA

<sup>d</sup> Center for the Neural Basis of Cognition, USA

Received 1 July 2004; received in revised form 14 March 2005; accepted 18 March 2005

### Abstract

The left inferior parietal cortex has been claimed to be the site of the verbal short-term store, yet imaging studies report activity of a homologous right-hemisphere region in verbal working memory tasks as well. In spite of its prevalent activity, right parietal contributions to verbal working memory are poorly understood. To clarify its role in verbal working memory performance, we tested a patient with a lesion in the right parietal lobe on verbal and spatial versions of the *N*-back task. The patient was impaired in all the spatial conditions regardless of load (0-, 1-, and 2-back), whereas in the verbal *N*-back he was impaired only in the conditions with a memory demand (1- and 2-back). Given that we had presented stimuli at multiple locations in the verbal *N*-back, however, it remained possible that the lesion impaired spatial representation rather than verbal working memory per se. With central stimulus presentation, his performance dramatically improved indicating that his difficulty with the *N*-back task was largely due to his poor visuospatial abilities.

© 2005 Elsevier Ltd. All rights reserved.

**Keywords:** Parietal cortex; Verbal working memory; Spatial processing; *N*-back

Neuroscientists have an unprecedented number of methodologies available to them for investigating neural function. In the domain of verbal working memory, event-related potentials (Gevins & Smith, 2000), imaging techniques such as PET (Paulesu, Frith, & Frackowiak, 1993; Smith, Jonides, & Koeppe, 1996) and fMRI (Cohen et al., 1997; D'Esposito, Zarahn, Aguirre, & 1999), and neuropsychological (Martin & Saffran, 1997; Vallar, DiBetta, & Silveri, 1997) and clinical investigations (Schlosser et al., 2003) have all been used as a means to explore the neural substrates involved in remembering verbal items. When neural regions are consistently implicated in verbal working memory studies independent of methodology, it strongly supports the notion that those regions are necessary for remembering

verbal information. However, when regions are not reported consistently and there are discrepancies across methodologies, it becomes ambiguous as to whether those regions are essential to verbal working memory performance. The focus of this paper is on one region, the right parietal lobe, which is often reported to be activated in imaging studies of verbal working memory, but has not been commonly associated with memory deficits in neuropsychological studies.

Imaging studies have demonstrated that bilateral parietal regions are engaged when verbal information has to be recalled from short-term memory (Davachi, Maril, & Wagner, 2001; D'Esposito et al., 1998; Henson, Burgess, & Frith, 2000; Jonides et al., 1997; Majerus et al., 2003). Moreover, bilateral parietal activity is apparent across a range of verbal working memory tasks regardless of the type of verbal item (e.g., letters, words, or digits) to be remembered (Clark et al., 2000; Cohen et al., 1997; Davachi et al., 2001; Glabus et al., 2003; Petrides, Alivisatos, Meyer, & Evans, 1993; Smith et al., 1996), type of retrieval (e.g., recall or recognition)

\* Corresponding author at: UC Davis Imaging Research Center, 4701 X Street, Sacramento, CA 95817, USA. Tel.: +1 916 734 3944; fax: +1 412 624 9149.

E-mail address: susan.ravizza@ucdmc.ucdavis.edu (S.M. Ravizza).

(Clark et al., 2000; Henson et al., 2000; Majerus et al., 2003; Schumacher et al., 1996), or the necessity of serial order information (Braver et al., 1997; Marshuetz, Smith, Jonides, DeGutis, & Chenevert, 2000). Whereas the left parietal cortex has been claimed to be the verbal short-term store (Jonides et al., 1998; Paulesu et al., 1993; but see Ravizza et al., 2004), imaging studies have been equivocal with regard to the function of the homologous right parietal region in verbal working memory tasks.

The involvement of the right parietal cortex in tasks ranging from spatial working memory (De Renzi, Faglioni, & Previdi, 1977; Malhotra et al., 2005; Mannan et al., 2005; Owen et al., 1998; Reuter-Lorenz et al., 2000; Smith et al., 1996; Zurowski et al., 2002), task switching (Behrmann, Geng, & Shomstein, 2004; Le, Pardo, & Hu, 1998), sustained attention (Corbetta, Kincade, & Shulman, 2002; Coull, Frith, Frackowiak, & Grasby, 1996; Pardo, Fox, Raichle & 1991; Wojciulik & Kanwisher, 1999), and response selection (Bunge, Hazeltine, Scanlon, Rosen, & Gabrieli, 2002; Hazeltine, Bunge, Scanlon, & Gabrieli, 2003; Sylvester et al., 2003) does not allow for a straightforward interpretation of its contribution to verbal working memory tasks. Whereas some researchers have attributed right parietal activity to the necessity of spatial processing in some verbal working memory tasks, others have attributed more domain-general functions to the right parietal lobe, such as selective attention, that may be required when performing verbal working memory tasks. Both domain-specific (i.e., spatial coding) and domain-general accounts of right parietal contributions to verbal working memory are supported by the literature making it difficult to adjudicate between them.

Damage to the right parietal cortex is strongly linked with spatial neglect (Heilman and Van den Abell, 1979; Mesulam, 1981; Mort et al., 2003; Posner, Walker, Friedrich, & Rafal, 1984, but see, Karnath et al., 2001), and activity of this region is observed in imaging studies of spatial processing. These findings suggest that this region may contribute domain-specific spatial processes to verbal working memory tasks. For instance, some researchers have suggested that the right parietal lobe may assist in the use of visuospatial imagery strategies to remember verbal items (Clark et al., 2000; Honey, Bullmore, & Sharma, 2000; Salmon et al., 1996). Indeed, most imaging studies of verbal working memory have presented letters or words visually. If verbal items are presented at different locations, spatial processing may be helpful by adding another route for recalling verbal information. In addition to encoding spatial location, the right parietal lobe may be important for the recognition of visually presented letters or words. For example, Caramazza and Hillis (1990a, 1990b) reported that the reading abilities of their neglect patient were affected by the nature of his spatial representation problems.

This issue could be resolved by proposing a domain-general function of the right parietal cortex that would be needed in both auditory and visual verbal tasks. In particular, this region may be important for attending selectively to in-

formation across auditory and visual modalities (Behrmann et al., 2004; Pugh et al., 1996) regardless of whether the items to be remembered are spatial or nonspatial (Wojciulik & Kanwisher, 1999). For example, Wojciulik and Kanwisher demonstrated that overlapping right parietal regions were engaged in a variety of visual attention tasks such as peripheral shifting, object matching, and a nonspatial conjunction task. Other studies have proposed that this region is important when attention must be shifted (Gurd et al., 2002; Le et al., 1998; Yantis & Serences, 2003). Consistent with these findings, it has been suggested that parietal cortex may shift attention between items in memory in order to keep them active (Chein, Ravizza, & Fiez, 2003; Jonides et al., 1998; LaBar, Gitelman, Parrish, & Mesulam, 1999).

A third possibility is that activation of the right parietal cortex is epiphenomenal; that is, in particularly demanding tasks, increased activity of the left parietal cortex may result in activity of the homologous right parietal region because of the abundance of connections between these two regions (see Just et al., 1996 for an analogous argument concerning the right-hemisphere homologue to Broca's area). In this sense, right parietal activity would be largely nonfunctional. Indeed, neuropsychological reports are unclear as to whether the right parietal lobe is necessary for successful recall. A case study of a patient with a right inferior parietal lesion reported normal recall of digits in both forward (10 items) and backward order (5 items) (Husain et al., 2001). In contrast, another right parietal patient was extremely impaired and could only recall three digits despite intact phonological perception and word comprehension (Berndt & Mitchum, 1990).

In order to bridge the gap between the neuroimaging and neuropsychological literatures, we tested a patient with a right parietal lesion on a task often used in imaging studies of working memory, the *N*-back task. Of interest is whether our results using a neuropsychological approach will confirm the results of imaging studies; that is, will a right parietal patient be impaired on the same task that evokes robust right parietal activity using imaging techniques? Our first goal was to assess whether the right parietal lobe is functionally necessary for successful recall of verbal information or if it is simply epiphenomenal. If right parietal cortex damage is associated with impaired performance on a verbal working memory task, we will then determine whether right parietal contributions are tied to the visuospatial domain or whether it has a more general role in executive control or attentional processing.

## 1. Experiment 1

The goal of the first experiment was to determine whether the right parietal cortex contributes to successful recall of verbal items. Hence, we tested a right parietal patient on a verbal *N*-back task where the goal was to remember whether a letter was the same as one presented *n* trials previously. Imaging studies of verbal working memory often use this task to assess the neural substrates of verbal recall and the

right parietal cortex has demonstrated robust activity in these studies (Braver et al., 1997; Clark et al., 2000; Cohen et al., 1997; D'Esposito et al., 1998; Honey et al., 2000; Jonides et al., 1997; Ravizza, Delgado, Chein, Becker, & Fiez, 2004; Schumacher et al., 1996). We also tested this patient on a spatial version of the *N*-back task. Given that this patient exhibited symptoms of extinction for visual stimuli in the contralateral hemifield, we suspected that spatial processing as well as spatial working memory would be impaired (although we tried to minimize the effects of extinction by presenting the stimuli in a vertical column). However, this task was useful in assessing whether verbal memory was relatively spared in comparison to spatial working memory. If right parietal activity is epiphenomenal, then verbal working memory should be spared relative to spatial working memory. If the right parietal lobe does make a functional contribution to verbal working memory, then the patient should be impaired on both the spatial and verbal working memory tasks.

### 1.1. Methods

**Patient details.** RB is a 69-year-old man with a bachelor's degree. In 1987, he was diagnosed with a right parietal arteriovenous malformation (AVM). He suffered a right parieto-occipital intercerebral hemorrhage in 1993 after which he underwent surgery for embolization and resection (see Fig. 1a). His most recent CT scan (2003) indicates damage to the right parietal, temporal, and occipital lobe (90 cc), no evidence of a midline shift, but prominent ventricles and sulci consistent with age-related volume loss. The lesion encompassed the superior parietal lobe, intraparietal sulcus, posterior aspects of the superior temporal and angular gyri, the white matter underlying the middle temporal lobe, and the occipital lobe.

To ensure that RB's lesion corresponded to right parietal regions reported in verbal working memory studies, we con-

ducted a meta-analysis of parietal sites observed in 42 verbal working memory studies. Using the stereotaxic coordinates of the peaks of activity reported in Table 1, we created an image of the points within a  $256 \times 256 \times 256$  matrix and then smoothed the image with a Gaussian filter (15 mm FWHM) (see Table 1 for references). This image was then overlaid on a reference brain that had been transformed into stereotaxic space with the same resolution. As can be observed in Fig. 1b, RB's lesion encompassed regions in the superior parietal cortex and the intraparietal sulcus that are active in verbal working memory tasks. Brighter colors in this figure indicate greater overlap of points of peak activity. Note that nearly identical regions in the left-hemisphere are also recruited in verbal working memory tasks (Ravizza et al., 2004). The number of points contributing at least half of their Gaussian value to the voxel of greatest overlap was 29/74 for the left parietal region (peak:  $x = -32, y = -53, z = 41$ ) and 19/64 for the right parietal region (peak:  $x = 33, y = -57, z = 44$ ).

RB exhibited moderate neglect when he was administered the Behavioral Inattention Test in 1995 (see Cate and Behrmann, 2002). In confrontation testing, RB manifested symptoms of extinction; that is, he failed to detect the leftward stimulus only when it was accompanied by a concurrent stimulus on the right. We also tested RB on a standardized test of verbal working memory—the digits forward subtest of the Wechsler Memory Scale (Revised). The maximum number of digits that RB could recall in a forward sequence was six, which placed him in the 52nd percentile for his age group.

Also participating in this experiment were 13 control participants who were matched in age (mean = 66.8) and education (mean = 16.1 years) to RB. All control subjects had normal or corrected-to-normal vision, were right-handed, and had no history of neuropsychological disorders.

**Stimuli.** The verbal stimuli consisted of 18 English letters (B, C, D, F, G, H, J, K, M, N, P, Q, R, S, T, V, X, and Z)

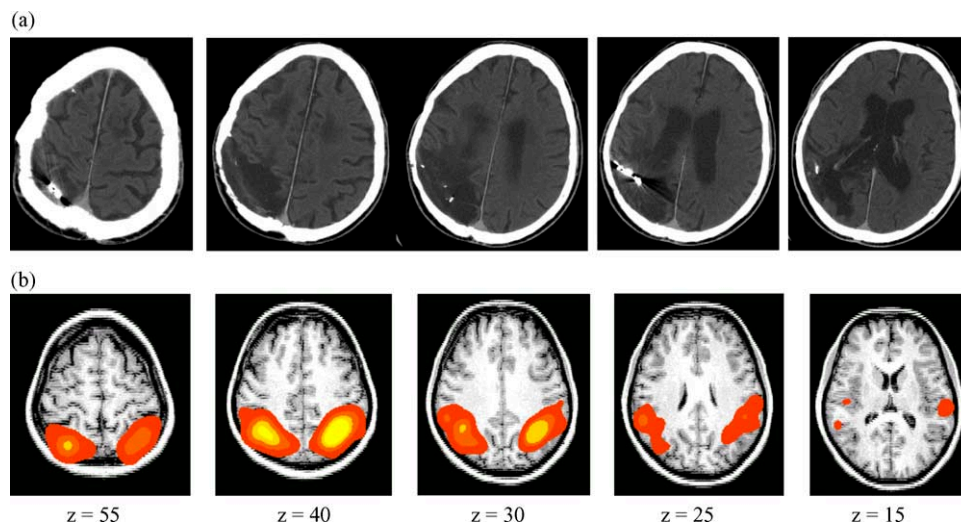


Fig. 1. (a) CT scan of patient RB revealing right parietal, temporal, and occipital damage and (b) results of our meta-analysis of right parietal regions reported in studies of verbal working memory. Note that  $z$ -values are estimated for RB's CT scans based on the determination of the AC-PC line observed in his scans (not presented here).

Table 1  
Stereotaxic coordinates of left and right parietal activity across 42 imaging studies of verbal working memory

	Left hemisphere			Right hemisphere		
Awh et al. (1996)	-17	-60	43	26	-58	45
Awh et al. (1996)				12	-64	47
Barch et al. (1997)	-40	-50	50			
Becker et al. (1996)	-58	-22	16	42	-16	16
Braver et al. (1997)	-26	-60	45	32	-56	43
Bunge et al. (2000)	-30	-82	44	26	-80	48
Bunge et al. (2000)	-34	-66	40			
Bunge et al. (2000)	-46	-48	40			
Cabeza et al. (2002)	-35	-43	34			
Cabeza et al. (2002)	-49	-40	24			
Callicott et al. (1999)	-36	-58	52	44	-28	32
Chein and Fiez (2001)	-27	-58	43			
Clark et al. (2000)	-38	-58	40	40	-60	44
Cohen et al. (1997)	-40	-48	40	12	-61	53
Cohen et al. (1997)	-28	-41	41	44	-55	43
Cohen et al. (1997)				37	-44	39
Coull et al. (1996)	-28	-60	36	24	-64	36
Coull et al. (1996)	-32	-54	40	22	-68	32
Coull et al. (1996)	-30	-54	40			
Crottaz-Herbette et al. (2004)	-52	-44	46	42	-52	44
Crottaz-Herbette et al. (2004)	-52	-44	46	52	-44	46
Crottaz-Herbette et al. (2004)	-36	-58	56			
Davachi et al. (2001)	-24	-60	45	30	-60	45
Davachi et al. (2001)				27	-60	51
de Zubicaray et al. (1998)	-35	-36	42	58	-36	31
de Zubicaray et al. (1998)				23	-67	48
de Zubicaray et al. (1998)				26	-58	37
de Zubicaray et al. (1998)				40	-69	26
de Zubicaray et al. (1998)				55	-39	26
de Zubicaray et al. (1998)				52	-17	20
D'Esposito et al. (1998)	-30	-60	38	30	-53	41
Gisselgard et al. (2003)	-38	-50	46			
Glabus et al. (2003)	-44	-41	43	44	-46	43
Gruber (2001)	-40	-40	48	32	-64	52
Gruber (2001)	-56	-56	44	52	-56	44
Gruber (2001)	-60	-44	28	56	-44	24
Henson et al. (2000)	-24	-64	47	27	-54	51
Henson et al. (2000)	-51	-39	36	57	-33	42
Herwig et al. (2003)	-37	-51	56			
Herwig et al. (2003)	-28	-55	35			
Herwig et al. (2003)	-48	-38	48			
Honey et al. (2000)	-35	-53	37			
Jonides et al. (2000)	-24	-58	43			
Jonides et al. (2000)	-28	-53	40			
Jonides et al. (1997)	-21	-67	36			
Jonides et al. (1997)	-35	-51	38	35	-49	40
Jonides et al. (1997)	-35	-49	36	30	-58	40
Jonides et al. (1998)	-21	-64	36	42	-51	40
Jonides et al. (1999)				30	-60	38
LaBar et al. (1999)				45	-60	33
Majerus et al. (2003)	-24	-49	37	34	-37	31
Marshuetz et al. (2000)	-34	-46	46	34	-54	47
Marshuetz et al. (2000)	-36	-48	50	36	-56	47
Marshuetz et al. (2000)	-30	-44	46	26	-56	52
Martin et al. (2003)	-29	-58	-36	47	-59	38
Martin et al. (2003)	-56	-19	19			
Paulesu et al. (1993)	-44	-32	24	54	-32	24
Paulesu et al. (1996)	-44	-34	24	54	-42	20
Petrides, Alivisatos, Meyer, and Evans (1993)	-38	-50	42	31	-64	49
Petrides et al. (1993)	-35	-49	40	19	-66	42
Petrides et al. (1993)				42	-44	49
Petrides et al. (1993)				38	-52	45
Petrides et al. (1993)				31	-62	42

Table 1 (Continued)

	Left hemisphere			Right hemisphere		
Petrides et al. (1993)				42	−44	49
Reuter-Lorenz et al. (2000)	−30	−58	43			
Reuter-Lorenz et al. (2000)	−33	−51	38			
Rypma and D’Esposito (1999)	−25	−63	45			
Rypma and D’Esposito (1999)	−30	−53	32			
Rypma and D’Esposito (1999)	−49	−34	45			
Sakai, Rowe, and Passingham (2002)	−44	−36	40	38	−40	44
Salmon et al. (1996)	−50	−52	32	36	−66	32
Salmon et al. (1996)	−56	−22	24	44	−56	36
Salmon et al. (1996)	−58	−26	20	42	−46	32
Salmon et al. (1996)				34	−44	36
Schumacher et al. (1996)	−8	−67	43	12	−67	43
Schumacher et al. (1996)	−26	−62	45	15	−62	45
Schumacher et al. (1996)	−28	−60	40	39	−46	36
Schumacher et al. (1996)	−39	−42	38			
Schumacher et al. (1996)	−39	−51	40			
Smith et al. (1996)	−17	−60	45	26	−55	50
Smith et al. (1996)	−33	−46	38	10	−64	47
Smith et al. (1996)	−24	−55	43	12	−64	47
Smith et al. (1996)	−37	−49	40			
Speck et al. (2000)	−28	−56	60	30	−60	58
Speck et al. (2000)	−26	−62	58	36	−64	56
Tsukiura et al. (2001)	−24	−72	52	40	−60	44
Tsukiura et al. (2001)	−38	−52	52			
Walter et al. (2003)	−24	−66	51	30	−63	54
Walter et al. (2003)	−33	−48	39	39	−48	39
Walter et al. (2003)				50	−53	41

that were presented at one of 10 possible locations in the display.

*Procedure.* Stimulus presentation was identical in both the verbal and spatial versions of the *N*-back task (Fig. 2).




Fig. 2. Examples of the 2-, 1-, and 0-back tasks for both the verbal and spatial conditions in the *N*-back paradigm.

Letters were presented every 3 s at different locations along a vertical axis centered in the middle of the screen. Aligning the letters along the vertical axis ensured that stimuli would not be subject to any possible effects of spatial extinction. Letters were presented at one of 10 locations that were spaced equally along a 768 pixel-long axis and presented on a 14 in. monitor.

In the low-load version of the *N*-back (0-back) task, participants were asked to press a button with their right index finger if a specific target appeared. The target was the letter “X” in verbal blocks and the target was the center of the screen in the spatial conditions. If any other item besides the target appeared on the screen, participants were asked to press a button with their right middle finger. In the spatial 0-back, the center target letter and its two nearest distracters were spaced more closely than the distracters were to each other. As a result, participants often mistook letters presented just above and below center as being presented in the center. To adjust for these errors, all responses to stimuli at the two closest positions were counted as correct.

Participants were also tested on blocks of the 1- and 2-back tasks. In these conditions, participants determined whether an item was the same as the letter or location presented one or two trials back. If the letter or location was the same, participants pressed the button under their right index finger and the button under their right middle finger if it was different. In the verbal 1- and 2-back tasks, participants were encouraged to rehearse the letters presented in the last one or two trials while continuously updating their list as each new letter appeared. Items in both the verbal and spatial *N*-back tasks

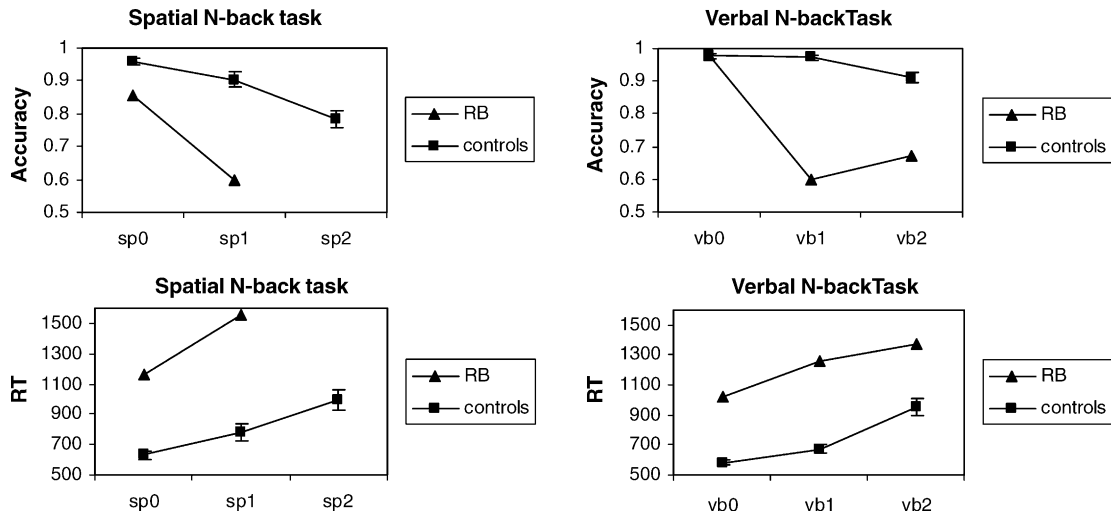


Fig. 3. Accuracy and RT of control subjects and RB on the verbal and spatial *N*-back tasks in Experiment 1.

were visible for 500 ms and an interval of 2500 ms elapsed before the next letter appeared. Twelve items were presented in each block of trials and participants performed one practice and four experimental blocks of each condition. RB became frustrated after one block of the spatial 2-back condition and declined to continue with that task.

The probability of an item being a target was 25%, whereas new distracters and repeated distracters appeared 64% and 11% of the time, respectively. In the verbal *N*-back conditions, letters appeared at randomly chosen locations. Similarly, letters were chosen randomly in the spatial conditions.

1.2. Results and discussion

Consistent with his profound deficit in spatial processing, RB was severely impaired in all of the spatial *N*-back conditions regardless of memory load (see Fig. 3). Although he performed as well as controls in the verbal (0-back) detection task, RB's performance in the verbal memory conditions was quite poor (Table 2). RB's mean accuracy on all tests, except the verbal 0-back task, was outside the 99% confidence interval predicted from the control data (d.f. = 1,12). RB was also much slower than controls in all conditions (all RTs were outside the 99% confidence interval). Thus, RB was impaired at the spatial tasks regardless of memory demands whereas, in the verbal task, he only differed from controls in the two memory conditions (i.e., the 1- and 2-back versions).

These results confirm the importance of the right parietal cortex in at least one paradigm often employed in imaging studies of verbal working memory. Although we predicted that RB would have difficulty with the spatial baseline and memory conditions, he showed no sparing of performance in the verbal working memory tasks; that is, RB's accuracy in the verbal and spatial 1-back was exactly the same (61%). Thus, we are able to discard the notion that activity of right parietal areas is always epiphenomenal; that is, verbal recall does rely on processes contributed by this area in some working memory tasks. As RB did not exhibit a selective spatial working memory deficit, it may be that the *N*-back requires a domain-general function provided by the right parietal cortex that is used in both spatial and verbal conditions (e.g., selective attention, switching between items in memory).

Alternatively, RB's poor visuospatial abilities which are evident in his substandard performance in the spatial encoding baseline (i.e., 0-back) condition may have affected his ability to remember verbal items. Given that letters appeared at random locations, spatial information may be useful in that it supplies another route through which verbal items could be accessed and remembered. Further, accurate letter encoding may rely on perceptual processes contributed by the right parietal lobe. In fact, simply searching the display for the letter may require intact right parietal functioning. Besides these direct effects of RB's spatial impairments on verbal working memory performance, effortful and slow spatial processing

Table 2

Confidence intervals calculated from the mean accuracy and standard error of control participants in Experiments 1 and 2

99% confidence interval (95%)	0-back			1-back			2-back		
	Lower	Upper	RB	Lower	Upper	RB	Lower	Upper	RB
Spatial	.93(.94)	.99(.98)	0.85	.83(.85)	.98(.96)	0.6	.70(.73)	.86(.83)	NA
Verbal(random)	.96(.96)	.99(.99)	0.98	.96(.95)	.99(.99)	0.6	.86(.88)	.96(.94)	0.67
Verbal(central)	.97(.98)	1(1)	1	.93(.95)	1(.98)	0.86	.87(.90)	1(1)	0.88
Verbal (central)–verbal (random)	−.05(−.02)	.09(.06)	0.02	−.06(−.04)	.03(.01)	0.26	−.06(−.02)	.15(.11)	0.21

may have indirectly reduced his span by leaving less time to rehearse items in memory. In any case, all these are examples of how the domain-specific process of spatial encoding could affect the ability to remember verbal items. The opposite case, that spatial memory is affected because right parietal verbal functions are impaired, is unlikely given that RB's accuracy in the verbal baseline condition was equivalent to that of the control participants.

As our version of the *N*-back task required a high degree of both executive control and visuospatial processing, we are unable to dissociate between a domain-general versus a more domain-specific/spatial account of right parietal contributions to verbal working memory tasks. In the next experiment, we will decrease demands on spatial processing by presenting letters in a fixed location (i.e., the center of the screen) while keeping the requirement for executive control the same.

## 2. Experiment 2

In the previous experiment, we demonstrated that successful recall of verbal items presented at random locations was impaired following damage to the right parietal cortex. This confirms previous neuroimaging studies that report right parietal activity in verbal working memory tasks when items are presented at varying locations (Smith et al., 1996; Walter et al., 2003; Zurowski et al., 2002). However, this region is also active in imaging studies when letters are presented centrally (Cohen et al., 1997; Jonides et al., 1997; Ravizza et al., 2004; Schumacher et al., 1996). If RB is unimpaired at the *N*-back task with central presentation, then the evidence would support a role for a right parietal cortex in visuospatial processing rather than executive control.

### 2.1. Methods

**Participants.** RB and five of the control participants (mean = 60.2 years old and 15 years of education) were retested in a separate session for Experiment 2.

**Stimuli.** Stimuli were identical to those described in Section 1.

**Procedure.** The only differences in procedure between Experiments 1 and 2 was that letters were presented sequentially in a single location, positioned at the center of the screen, rather than at random locations along a vertical axis and only the verbal version of the *N*-back task was conducted.

### 2.2. Results and discussion

RB's accuracy in both the working memory conditions (1- and 2-back) improved dramatically when letters were presented centrally, and he was able to respond quickly across all conditions (see Fig. 4). RB's mean improvement in the 1- and 2-back tasks fell outside the 99% confidence range (d.f. = 1,4) calculated from the standard error and mean ac-

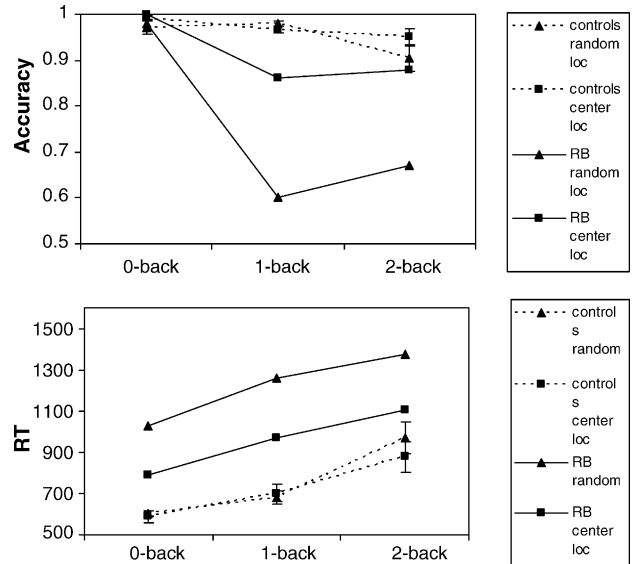


Fig. 4. Accuracy and RT of control subjects (squares) and RB (triangles) on the verbal *N*-back task where letters were presented centrally (dashed lines) or at random locations (solid lines).

curacy of the control group (Table 2). RB's improvement in the 0-back task was equivalent to controls and fell within the 95% confidence interval.

While RB's larger than normal improvement may reflect ceiling effects in the control subjects, additional evidence suggests otherwise. For instance, the accuracy of the control subject with the poorest performance with random presentation (83% correct in the 2-back condition) only improved 7% with central presentation whereas RB showed gains of about 20% in accuracy. Furthermore, control participants' RT (a dependent variable that is more immune to ceiling effects) did not improve at all whereas RB was able to respond more quickly when letters were presented centrally. As a further test of RB's improvement, we asked a patient with cerebellar damage (age = 79; education = PhD) to perform the *N*-back with letters presented either randomly or centrally. Given that the cerebellum is often implicated in imaging studies of verbal working memory, potentially by aiding articulatory rehearsal (Paulesu et al., 1993), we would predict that central presentation should have less impact on this patient's performance compared to RB. With random presentation, the cerebellar patient's accuracy in the 2-back task was 81%, which was at the bottom of the range of control participants. When letters were presented centrally, the patient's improvement was on par with that of the least accurate control (i.e., 9%) and was within the 95% confidence interval calculated from the control data. Taken together, this evidence suggests that presenting letters centrally was much more beneficial for the right parietal patient than for either control participants or a neurological control.

The results of this experiment suggest that a large portion of RB's difficulty with verbal recall in Experiment 1 was due to the random placement of letters in space. This implies

that the parietal lobe is contributing domain-specific spatial processes. When spatial computations are not needed to perform the task, the role of the right parietal cortex diminishes even when executive control is inherent to the task. However, RB still displayed a residual impairment in the verbal memory conditions, especially the 1-back task, despite presenting stimuli centrally. RB's accuracy in the 1-back condition fell outside the 99% confidence interval while his accuracy in the 2-back task was between the 95% and 99% confidence ranges. Given that imaging studies also report right parietal involvement when stimuli are presented centrally, these results indicate either (1) that spatial information is helpful to verbal working memory even with central fixation (e.g., letter encoding, maintenance of attentional focus) or (2) that the parietal lobe is contributing both attentional and spatial processes.

There is some evidence for the former explanation. In a behavioral study, Meegan, Purc-Stephenson, Honsberger and Topan (2004) demonstrated that, in an *N*-back task where stimuli were presented centrally, accuracy was disrupted by both verbal and spatial response tasks. They suggest that spatial processing is inherent to verbal *N*-back tasks even when stimuli are presented at a central location. Moreover, other research has shown that neglect patients have difficulty when identifying letters in a rapid visual stream (Husain, Shapiro, Martin, & Kennard, 1997) even when they are presented at fixation. RB's poorer performance in the 1-back compared to the 2-back task in both experiments suggests that his slowness in processing visual stimuli may be affecting verbal recall. If letter identification takes longer for RB, he may not have completed letter encoding by the time he is required to make a decision concerning the current stimulus in the 1-back task. In contrast, RB will have had more time to finish encoding a letter that was presented two trials back. Given RB's leftward visual extinction, it is possible that he was biased in Experiments 1 and 2 to respond more with his middle than his index finger. To estimate the degree of response bias, the proportion of all responses that were leftward was subtracted from the proportion of leftward responses required by the experiment (on average, 25% of participants' responses should have been leftward as this designated a target). In Experiment 1, RB displayed a slight rightward bias compared to controls (5% versus -1%) whereas in Experiment 2 both RB and controls displayed equivalent degrees of rightward response bias (~1%).

### 3. General discussion

Imaging studies have demonstrated that the right parietal cortex is active during verbal working memory tasks, but it is unclear whether this region is necessary for successful verbal recall based on the imaging literature alone. The experiments reported here constitute the first systematic exploration of right parietal contributions to verbal working memory and demonstrate that this region is important for successful performance under some conditions.

The right parietal patient described in this paper was particularly suitable for these experiments given that his frontal cortex was spared. The dorsolateral prefrontal cortex has been associated with the "central executive" component of working memory, and is thought to enable the manipulation of items within memory (D'Esposito et al., 1998; Tsukiura et al., 2001) as well as enhancing attention to increase span (Rypma & D'Esposito, 1999). Thus, any verbal working memory deficits exhibited by this patient cannot be attributed to executive processing provided by the dorsolateral prefrontal cortex.

Although we can rule out frontal contributions to RB's working memory performance, we have not controlled for potential effects of concomitant damage to the temporal and occipital lobe. There are several reasons why we believe that RB's working memory impairment was primarily due to his impaired parietal cortex. First, temporal and occipital regions are not consistently activated across verbal working memory tasks (Cabeza & Nyberg, 2000). Second, sensory processes that would rely on an intact temporal and occipital lobe were relatively unimpaired. For example, in the visual domain, RB could accurately identify the target in the low-load *N*-back task and had a normal auditory verbal span as assessed by the digit forward subtest of the WAIS (see Section 1.1). Third, RB's primary difficulty with verbal working memory tasks are best accounted for as resulting from impairments in spatial processing, a deficit that has a long history of association with damage to the parietal cortex (see Behrmann et al., 2004 for a review; see Karnath et al., 2000 for an opposing view). Indeed, the lesions of neglect patients with spatial working memory deficits also overlap in the parietal lobe (Malhotra et al., 2005; Mannan et al., 2005). Although temporal and occipital damage may have affected RB's performance in our experiments, we believe the evidence more clearly indicates that RB's difficulty with verbal working memory tasks stems from a compromised parietal cortex.

Many have argued that the parietal cortex has domain-general executive functions (Chein et al., 2003; Jonides et al., 1998; Marshuetz et al., 2000; Wojciulik & Kanwisher, 1999). For example, Wojciulik and Kanwisher (1999) claim that this region is important for directing attention to stimuli regardless of domain (e.g., spatial, object, verbal). The fact that RB was unimpaired at serial recall in the auditory domain argues against this claim as well as ideas that posit a domain-general role for the parietal cortex in shifting attention between items in working memory (Chein et al., 2003). Moreover, RB was almost as accurate as controls in a task with high executive demands, the *N*-back task, when items were presented centrally (Experiment 2).

In contrast, when demands on spatial processing are high in verbal working memory tasks, reliance on right parietal functions becomes greater. In Experiment 1, we demonstrated that varying the spatial locations of verbal stimuli caused a right parietal patient, RB, to have difficulty remembering verbal items. In contrast, RB's verbal recall improved dramatically when stimuli were presented in a fixed location



(Experiment 2). Moreover, RB exhibited a selective deficit for verbal information in the visual modality. On an auditory test of verbal working memory, immediate serial recall (see digit span data in Section 1.1), RB performed normally. These results argue strongly for an interpretation of right parietal function along the line of spatial processing rather than a more general involvement in attentional/central executive functions in verbal working memory tasks. Although the right parietal cortex may be involved in some executive processing (e.g., task switching), these domain-general functions appear unnecessary for successful verbal recall.

Note, however, that we do not present evidence of intact performance on an auditory version of a verbal working memory task that requires a high degree of cognitive control such as the *N*-back task. Intact performance on this task would have provided additional evidence for our proposal that parietal cortex primarily contributes spatial rather than domain-general executive and attentional processes to the performance of verbal working memory tasks. Unfortunately, RB's deteriorating health did not allow us to test him on such tasks; however, we suspect that RB would not have done well on an auditory *N*-back task. Tasks that place greater demands on cognitive control such as the *N*-back task or backwards recall tend to promote the use of dual coding strategies. For example, both verbal and spatial codes are used to maintain items in the *N*-back task (Meegan et al., 2004) and recalling verbal items in a reverse sequence (Li & Lewandowsky, 1995). Discovering working memory tasks that tap executive processing while discouraging the use of dual coding strategies will be important for future research.

We have demonstrated that verbal working memory deficits are associated with damage to the right parietal cortex when spatial processing is necessary for successful performance. These results are suggestive of a visuospatial contribution of the right parietal cortex to verbal working memory tasks and are consistent with reports of right parietal activity in verbal working memory tasks. Although this is a good start in explaining right parietal contributions to verbal working memory, many outstanding questions remain concerning the particular way in which this region facilitated memory performance. For example, we did not address whether this region is recruited when having to search the target display for verbal items appearing at random locations, for encoding spatial aspects of letters and words, or for maintaining visuospatial attention at a central location. Although these issues are not resolved in the context of this paper, these studies have generated questions that need to be addressed in order to fully understand right parietal function in general, and in verbal working memory tasks specifically.

## Acknowledgements

This research was supported by NIH grant RO1 MH59256 to JAF and NIMH grant MH54246 to MB. We would like to thank Dr. Joseph Ricker for his assistance in obtaining high-

resolution CT images. We would also like to thank Jason Chein for helpful debates and technical assistance.

## References

- Awh, E., Jonides, J., et al. (1996). Dissociation of storage and rehearsal in verbal working memory: Evidence from positron emission tomography. *Psychological Science*, *7*(1), 25–31.
- Barch, D. M., Braver, T. S., Nystrom, L. E., Forman, S. D., Noll, D. C., & Cohen, J. D. (1997). Dissociating working memory from task difficulty in human prefrontal cortex. *Neuropsychologia*, *35*(10), 1373–1380.
- Becker, J. T., Mintun, M. A., Aleva, K., Wiseman, M. B., Nichols, T., & DeKosky, S. T. (1996). Compensatory reallocation of brain resources supporting verbal episodic memory in Alzheimer's disease. *Neurology*, *46*(3), 692–700.
- Behrmann, M., Geng, J. J., & Shomstein, S. (2004). Parietal cortex and attention. *Current Opinion in Neurobiology*, *14*(2), 212–217.
- Berndt, R. S., & Mitchum, C. C. (1990). Auditory and lexical information sources in immediate recall: Evidence from a patient with deficit to the phonological short-term store. In G. Vallar & T. Shallice (Eds.), *Neuropsychological impairments of short-term memory* (pp. 115–144). New York: Cambridge University Press.
- Braver, T. S., Cohen, J. D., Nystrom, L. E., Jonides, J., Smith, E. E., & Noll, D. C. (1997). A parametric study of prefrontal cortex involvement in human working memory. *Neuroimage*, *5*, 49–62.
- Bunge, S. A., Hazeltine, E., Scanlon, M. D., Rosen, A. C., & Gabrieli, J. D. E. (2002). Dissociable contributions of prefrontal and parietal cortices to response selection. *Neuroimage*, *17*, 1562–1571.
- Bunge, S. A., Klinberg, T., Jacobsen, R. B., & Gabrieli, J. D. E. (2000). A resource model of the neural basis of executive working memory. *Proceedings of the National Academy of Science U.S.A.*, *97*(7), 3573–3578.
- Cabeza, R., & Nyberg, L. (2000). Imaging cognition II: An empirical review of 275 PET and fMRI studies. *Journal of Cognitive Neuroscience*, *12*(1), 1–47.
- Cabeza, R., Dolcos, F., Graham, R., & Nyberg, L. (2002). Similarities and differences in the neural correlates of episodic memory retrieval and working memory. *Neuroimage*, *16*, 317–330.
- Callicott, J. H., Mattay, V. S., et al. (1999). Physiological characteristics of capacity constraints in working memory as revealed by functional MRI. *Cerebral Cortex*, *9*(1), 20–26.
- Caramazza, A., & Hillis, A. E. (1990a). Levels of representation, coordinate frames, and unilateral neglect. *Cognitive Neuropsychology*, *7*(5/6), 391–445.
- Caramazza, A., & Hillis, A. E. (1990b). Spatial representation of words in the brain implied by studies of a unilateral neglect patient. *Nature*, *346*(6281), 267–269.
- Cate, A., & Behrmann, M. (2002). Spatial and temporal influences on extinction. *Neuropsychologia*, *40*(13), 2206–2225.
- Chein, J. M., & Fiez, J. A. (2001). Dissociation of verbal working memory system components using a delayed serial recall task. *Cerebral Cortex*, *11*(11), 1003–1014.
- Chein, J. M., Ravizza, S. M., & Fiez, J. A. (2003). Using neuroimaging to evaluate models of working memory and their implications for language processing. *Journal of Neurolinguistics*, *16*(4/5), 315–339.
- Clark, C. R., Egan, G. F., McFarlane, A. C., Morris, P., Weber, D., Sonkilla, C., et al. (2000). Updating working memory for words: A PET activation study. *Human Brain Mapping*, *9*(1), 42–54.
- Cohen, J. D., Perlstein, W. M., Braver, T. S., Nystrom, L. E., Noll, D. C., Jonides, J., et al. (1997). Temporal dynamics of brain activation during a working memory task. *Nature*, *386*, 604–608.
- Corbetta, M., Kincade, J. M., & Shulman, G. L. (2002). Neural systems for visual orienting and their relationships to spatial working memory. *Journal of Cognitive Neuroscience*, *14*(3), 508–523.

- Crottaz-Herbette, S., Anagnoson, R. T., & Menon, V. (2004). Modality effects in verbal working memory: Differential prefrontal and parietal responses to auditory and visual stimuli. *Neuroimage, 21*, 340–351.
- Coull, J. T., Frith, C. D., Frackowiak, R. S., & Grasby, P. M. (1996). A fronto-parietal network for rapid visual information processing: A PET study of sustained attention and working memory. *Neuropsychologia, 34*(11), 1085–1095.
- Davachi, L., Maril, A., & Wagner, A. D. (2001). When keeping in mind supports later bringing to mind: Neural markers of phonological rehearsal predict subsequent remembering. *Journal of Cognitive Neuroscience, 13*(8), 1059–1070.
- D'Esposito, M., Aguirre, G. K., Zarahn, E., Ballard, D., Shin, R. K., & Lease, J. (1998). Functional MRI studies of spatial and nonspatial working memory. *Cognitive Brain Research, 7*(1), 1–13.
- D'Esposito, M., Zarahn, E., & Aguirre, G. K. (1999). Event-related functional MRI: Implications for cognitive psychology. *Psychological Bulletin, 125*(1), 155–164.
- De Renzi, E., Faglioni, P., & Previdi, P. (1977). Spatial memory and hemispheric locus of lesion. *Cortex, 13*, 424–433.
- de Zubicaray, G. I., Williams, S. C., et al. (1998). Prefrontal cortex involvement in selective letter generation: A functional magnetic resonance imaging study. *Cortex, 34*(3), 389–401.
- Gevins, A., & Smith, M. E. (2000). Neurophysiological measures of working memory and individual differences in cognitive ability and cognitive style. *Cerebral Cortex, 10*(9), 829–839.
- Gisselgard, J., Petersson, K. M., Baddeley, A., & Ingvar, M. (2003). The irrelevant speech effect: a PET study. *Neuropsychologia, 41*, 1899–1911.
- Glabus, M. F., Horwitz, B., Holt, J. L., Kohn, P. D., Gerton, B. K., Callicott, J. H., et al. (2003). Interindividual differences in functional interactions among prefrontal, parietal and parahippocampal regions during working memory. *Cerebral Cortex, 13*(12), 1352–1361.
- Gruber, O. (2001). Effects of domain-specific interference on brain activation associated with verbal working memory task performance. *Cerebral Cortex, 11*, 1047–1055.
- Gurd, J. M., Amunts, K., Weiss, P. H., Zafiris, O., Zilles, K., Marshall, J. C., et al. (2002). Posterior parietal cortex is implicated in continuous switching between verbal fluency tasks: An fMRI study with clinical implications. *Brain, 125*, 1024–1038.
- Hazeltine, E., Bunge, S. A., Scanlon, M. D., & Gabrieli, J. D. E. (2003). Material-dependent and material-independent selection processes in the frontal and parietal lobes: An event-related fMRI investigation of response competition. *Neuropsychologia, 41*(9), 1208–1217.
- Heilman, K. M., & Van den Abell, T. (1979). Right hemispheric dominance for mediating cerebral activation. *Neuropsychologia, 17*(3-sup4), 315–321.
- Henson, R. N. A., Burgess, N., & Frith, C. D. (2000). Recoding, storage, rehearsal and grouping in verbal short-term memory: An fMRI study. *Neuropsychologia, 38*(4), 426–440.
- Honey, G. D., Bullmore, E. T., & Sharma, T. (2000). Prolonged reaction time to a verbal working memory task predicts increased power to posterior parietal cortical activation. *Neuroimage, 12*, 495–503.
- Husain, M., Mannan, S., Hodgson, T., Wojciulik, E., Driver, J., & Kennard, C. (2001). Impaired spatial working memory across saccades contributes to abnormal search in parietal neglect. *Brain, 124*(5), 941–952.
- Husain, M., Shapiro, K., Martin, J., & Kennard, C. (1997). Abnormal temporal dynamics of visual attention in spatial neglect patients. *Nature, 385*(6612), 154–156.
- Jonides, J., Marshuetz, C., Smith, E. E., Reuter-Lorenz, P. A., Koeppe, R. A., & Hartley, A. (2000). Age differences in behavior and PET activation reveal differences in interference resolution in verbal working memory. *Journal of Cognitive Neuroscience, 12*(1), 188–196.
- Jonides, J., Schumacher, E. H., Smith, E. E., Koeppe, R. A., Awh, E., Reuter-Lorenz, P. A., et al. (1998). The role of parietal cortex in verbal working memory. *Journal of Neuroscience, 18*(13), 5026–5034.
- Jonides, J., Schumacher, E. H., Smith, E. E., Lauber, E., Awh, E., Minoshima, S., et al. (1997). Verbal working memory load affects regional brain activation as measure by PET. *Journal of Cognitive Neuroscience, 9*(4), 462–475.
- Just, M. A., Carpenter, P. A., Keller, T. A., Eddy, W. F., Rep, M., van Dijk, J. M., et al. (1996). Brain activation modulated by sentence comprehension. *Science, 274*(5284), 114–116.
- Karnath, H. O., Ferber, S., et al. (2001). Spatial awareness is a function of the temporal not the posterior parietal lobe. *Nature, 411*(6840), 950–953.
- LaBar, K. S., Gitelman, D. R., Parrish, T. B., & Mesulam, M.-M. (1999). Neuroanatomic overlap of working memory and spatial attention networks: A functional MRI comparison within subjects. *Neuroimage, 10*, 695–704.
- Le, T. H., Pardo, J. V., & Hu, X. (1998). 4 T-fMRI study of nonspatial shifting of selective attention: Cerebellar and parietal contributions. *Journal of Neurophysiology, 79*, 1535–1548.
- Li, S.-C., & Lewandowsky, S. (1995). Forward and backward recall: Different retrieval processes. *Journal of Experimental Psychology: Learning, Memory, and Cognition, 21*(4), 837–847.
- Majerus, S., Laureys, S., Collette, F., Del Fiore, G., Degueldre, C., Luxen, A., et al. (2003). Phonological short-term memory networks following recovery from Landau and Kleffner syndrome. *Human Brain Mapping, 19*, 133–144.
- Malhotra, P., Jager, H. R., et al. (2005). Spatial working memory capacity in unilateral neglect. *Brain, 128*(Pt 2), 424–435.
- Mannan, S. K., Mort, D. J., Hodgson, T. L., Driver, J., Kennard, C., & Husain, M. (2005). Revisiting previously searched locations in visual neglect: Role of right parietal and frontal lesions in misjudging old locations as new. *Journal of Cognitive Neuroscience, 17*(2), 340–354.
- Marshuetz, C., Smith, E. E., Jonides, J., DeGutis, J., & Chenevert, T. L. (2000). Order information in working memory: fMRI evidence for parietal and prefrontal mechanisms. *Journal of Cognitive Neuroscience, 12*(Suppl. 2), 130–144.
- Martin, N., & Saffran, E. (1997). Language and auditory-verbal short-term memory impairments: Evidence for common underlying processes. *Cognitive Neuropsychology, 14*(5), 641–682.
- Martin, R. C., Wu, D., Freedman, M., Jackson, E. F., & Lesch, M. (2003). An event-related fMRI investigation of phonological versus semantic short-term memory. *Journal of Neurolinguistics, 16*(4–5), 341–360.
- Meegan, D. V., Purc-Stephenson, R., Honsberger, M. J. M., & Topan, M. (2004). Task analysis complements neuroimaging: An example from working memory research. *Neuroimage, 21*(3), 1026–1036.
- Mesulam, M. (1981). A cortical network for directed attention and unilateral neglect. *Annals of Neurology, 10*, 309–325.
- Mort, D. J., Malhotra, P., et al. (2003). The anatomy of visual neglect. *Brain, 126*(Pt 9), 1986–1997.
- Owen, A. M., Stern, C. E., Look, R. B., Tracey, I., Rosen, B. R., & Petrides, M. (1998). Functional organization of spatial and nonspatial working memory processing within the human lateral frontal cortex. *Proceedings of the National Academy of Sciences of the United States of America, 95*, 7721–7726.
- Pardo, J. V., Fox, P. T., & Raichle, M. E. (1991). Localization of a human system for sustained attention by positron emission tomography. *Nature, 349*, 61–63.
- Paulesu, E., Frith, C. D., & Frackowiak, R. S. (1993). The neural correlates of the verbal component of working memory. *Nature, 362*(6418), 342–345.
- Paulesu, E., Frith, U., et al. (1996). Is developmental dyslexia a disconnection syndrome? Evidence from PET scanning. *Brain, 119*(1), 143–157.
- Petrides, M., Alivisatos, B., Meyer, E., & Evans, A. C. (1993). Functional activation of the human frontal cortex during the performance of verbal working memory tasks. *Proceedings of the National Academy of Science, 90*, 878–882.

- Posner, M. I., Walker, J. A., Friedrich, F. J., & Rafal, R. D. (1984). Effects of parietal injury on covert orienting of attention. *Journal of Neuroscience*, *4*, 1863–1874.
- Pugh, K. R., Shaywitz, B. A., Shaywitz, S. E., Fulbright, R. K., Byrd, D., Skudlarski, P., et al. (1996). Auditory selective attention: An fMRI investigation. *Neuroimage*, *4*, 159–173.
- Ravizza, S. M., Delgado, M. R., Chein, J. M., Becker, J. T., & Fiez, J. A. (2004). Functional dissociations within the inferior parietal cortex in verbal working memory. *Neuroimage*, *22*(2), 562–573.
- Reuter-Lorenz, P. A., Jonides, J., Smith, E. E., Hartley, A., Miller, A., Marshuetz, C., et al. (2000). Age differences in the frontal lateralization of verbal and spatial working memory revealed by PET. *Journal of Cognitive Neuroscience*, *12*(1), 174–187.
- Rypma, B., & D'Esposito, M. (1999). The roles of prefrontal brain regions in components of working memory: Effects of memory load and individual differences. *Proceedings of the National Academy of Science*, *96*, 6558–6563.
- Sakai, K., Rowe, J. B., & Passingham, R. E. (2002). Parahippocampal reactivation signal at retrieval after interruption of rehearsal. *Journal of Neuroscience*, *22*(15), 6315–6320.
- Salmon, E., Van der Linden, M., Collette, F., Delfiore, P., Maquet, P., Degueldre, C., et al. (1996). Regional brain activity during working memory tasks. *Brain*, *119*, 1617–1628.
- Schlosser, R., Gesierich, T., Kaufmann, B., Vucurevic, G., Hunsche, S., Gawehn, J., et al. (2003). Altered effective connectivity during working memory performance in schizophrenia: A study with fMRI and structural equation modeling. *Neuroimage*, *19*, 751–763.
- Schumacher, E. H., Lauber, E., Awh, E., Jonides, J., Smith, E. E., & Koeppel, R. A. (1996). PET evidence for an amodal verbal working memory system. *Neuroimage*, *3*, 79–88.
- Smith, E. E., Jonides, J., & Koeppel, R. A. (1996). Dissociating verbal and spatial working memory using PET. *Cerebral Cortex*, *6*(1), 11–20.
- Speck, O., Ernst, T., Braun, J., Koch, C., Miller, E., & Chang, L. (2000). Gender differences in the functional organization of the brain for working memory. *Neuroreport*, *11*(11), 2581–2585.
- Sylvester, C.-Y. C., Wager, T. D., Lacey, S. C., Hernandez, L., Nichols, T. E., Smith, E. E., et al. (2003). Switching attention and resolving interference: fMRI measures of executive functions. *Neuropsychologia*, *41*, 357–370.
- Tsukiura, T., Fujii, T., Takahashi, T., Xiao, R., Inase, M., Iijima, T., et al. (2001). Neuroanatomical discrimination between manipulating and maintaining processes involved in verbal working memory: A functional MRI study. *Cognitive Brain Research*, *11*(1), 13–21.
- Vallar, G., DiBetta, A. M., & Silveri, M. C. (1997). The phonological short-term store-rehearsal system: Patterns of impairment and neural correlates. *Neuropsychologia*, *35*(6), 795–812.
- Walter, H., Bretschneider, V., Gron, G., Zurowski, B., Wunderlich, A. P., Tomczak, R., et al. (2003). Evidence for quantitative domain dominance for verbal and spatial working memory in frontal and parietal cortex. *Cortex*, *39*, 897–911.
- Wojciulik, E., & Kanwisher, N. (1999). The generality of parietal involvement in visual attention. *Neuron*, *23*, 747–764.
- Yantis, S., & Serences, J. T. (2003). Cortical mechanisms of space-based and object-based attentional control. *Current Opinion in Neurobiology*, *13*(2), 187–193.
- Zurowski, B., Gostomzyk, J., Gron, G., Weller, R., Schirrmester, H., Neumeier, B., et al. (2002). Dissociating a common working memory network from different neural substrates of phonological and spatial stimulus processing. *Neuroimage*, *15*, 45–57.